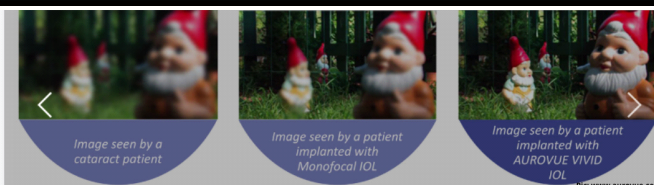


## Editorial Message

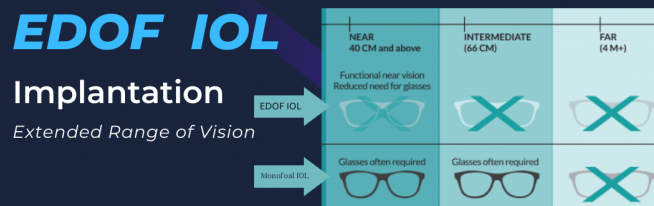
The theme of the current issue is on “Orbit, Oculoplastic and Ocular Oncology”. Oculoplasty evaluates and treats diseases and conditions affecting the eyelids, lacrimal (tear) system, orbit: bones and anatomical structures behind the eyeball, and adjacent areas of the face. It involves the plastics and reconstructive surgeries of above-mentioned structures.

On behalf of Academic and Training, we request everyone to come forward and join this teaching-learning interactive platform and impart knowledge, and experience through this newsletter.

Stay Safe; Happy Reading; and, Happy New Year-2023!



Extended depth of focus lenses have been shown to improve both intermediate and near vision



## In this Issue...

- ◆ Opening Remark 1  
Dr. Purnima Rajkarnikar
- ◆ Knowledge Pool 2-6  
Dr. Hom Bahadur Gurung  
Dr. Sushant Adiga  
Dr. Malita Amatya
- ◆ Case Story 4
- ◆ Sharing Experiences 4
- ◆ Photo Gallery 5
- ◆ Know Your Faculty 7  
Dr. Indira Paudyal
- ◆ The Staff Insight 7  
Ms. Karuna Shrestha
- ◆ Thank you / Subscriptions 8

INCEPTION

### Flex QY



#### Key Features:

- ◆ ISO 13485:2016 certified and DDA accredited product.
  - ◆ Aspheric Foldable Acrylic
  - ◆ Monofocal Yellow Tint
  - ◆ 360° Square Edge
  - ◆ Stable Haptic Design; Less Unfolding Time
  - ◆ Optic / Overall Sizes: 6mm / 13mm
  - ◆ Power Range +6.0D to +32.0D
- \*Product Inquiry: Calls: 01-4493775  
Email ID: dilip.koirala@tilganga.org

## White Reflex In Eye Is Not NORMAL

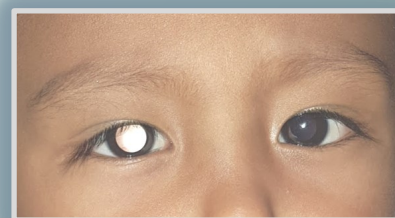

Dr Purnima Rajkarnikar

A mother of a one-year-old boy, from Dailekh, far western Nepal noticed white glow in the left eye of her son recently. She took her son to the local eye hospital from where he was promptly referred to TIO for further management. The boy was examined under anesthesia at TIO by us and diagnosed to have Retinoblastoma in both his eyes, larger and multiple tumors in his left retina and two smaller tumors in his right retina. CT scan was done which did not show any extraocular extension or optic nerve invasion. The final diagnosis being RE group B and LE group E Retinoblastoma, Stage 0.

He was referred to Kanti Children Hospital for metastatic workup and standard dose chemotherapy for 6 cycles. In between every chemo cycle, he underwent serial EUAs along with transpupillary thermotherapy (TTT) application to his better eye. After completing 6 doses of chemotherapy, he underwent LE enucleation with an implant with financial aid from Open Eyes Nepal since she could no longer afford her son's treatment. He received custom fit prosthesis in left socket and further 2 doses of TTT in RE with financial aid from the same organization. Currently, the boy is disease free but on regular on 3 monthly follow up.

Retinoblastoma represents 3% of all childhood cancers, and is the most common intraocular malignancy of childhood in the world. It is fatal if left untreated. Early detection can save life and eye. Worldwide prevalence is 1:15000 to 1:20000 live births. Exact prevalence in Nepal is not known but a recent survey conducted in multiple hospital records suggests that around 50 new cases are detected in Nepal each year. Among them, the Ocular oncology department of TIO sees 35 to 45 new cases per year with around 15 of them having bilateral diseases.



Treatment for Retinoblastoma is long, expensive and psychologically challenging to the parents and children. Stage 1 and 2 disease requires at least 6 months of systemic chemotherapy along with 4 weekly evaluations under anesthesia along with needful local treatment like transpupillary thermotherapy (TTT), cryotherapy and local chemo in the eye (periocular and intravitreal chemotherapy) until the tumor resolves completely. Many times, in spite of all the measures, the eye needs to be enucleated eventually to save the child's life. However, for children who present to hospital late, in stage 3 or 4 disease, there is an increased risk of mortality in spite of high dose 12 cycles of chemotherapy and radiation.

The rate of mortality in retinoblastoma (even with treatment) in the developed world is 5% while it is 40% in the developing world. This large discrepancy is due to early detection in the stage of “white eye reflex”, when life as well as the eye can likely be saved. In countries like Nepal, due to lack of awareness about this cancer among parents and even health care personnel, the children are often brought late in the course of disease. Late presentation means advanced disease requiring longer treatment duration and higher mortality and morbidity even with the treatment. All white eye reflexes (leukocoria) may not be retinoblastoma, but it is not the normal color of the pupil. It could be cataract or other congenital retinal problems which also need timely diagnosis and treatment.

Hence as health personnel we should spread an important message that- white reflex is not a normal reflex- refer the child immediately to higher center to save the eye and life.



**Dr. Hom Bahadur Gurung, MD**

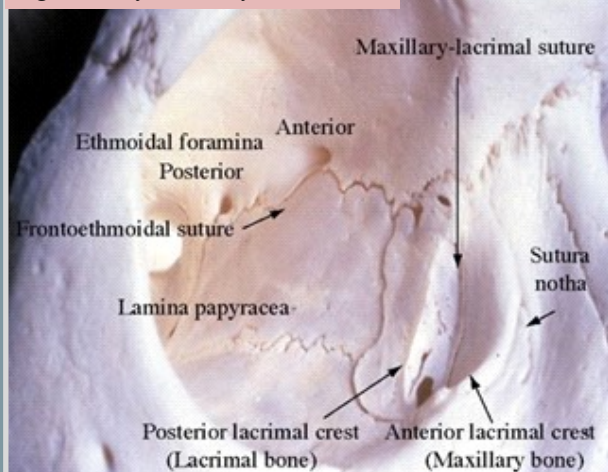
## Blood Less and Pain Less Dacryocystorhinostomy (DCR)

**E**xternal Dacryocystorhinostomy (DCR) under local anesthesia is not a favorite surgery among ophthalmologists. The two obvious reasons are pain and bleeding. Bloodless and painless DCR surgery under local anesthesia may be possible only in a perfect world but our patient as a living being bleed and feel pain. The aim is to achieve perfect DCR with minimum bleeding and minimum pain. Few steps to decrease the pain and bleeding are outlined as below.

### 1. Know your patient:

- Meticulous history and work up for bleeding disorders,
- Previous surgeries as repeat surgeries are usually painful,
- History of hypertension, blood thinners,
- Pain threshold as some are more tolerant to pain some would rather prefer general anesthesia,
- Trauma history. Traumatic Nasolacrimal duct obstruction (NLDO) has disrupted anatomy and will have more bleeding.
- A calm patient and a calm surgeon is a perfect combination. Counselling with realistic expectations and warnings about surgery will decrease anxiety as well as create bonds of trust. A mild sedative on the day of surgery may be helpful.

**Fig. 1: Bony Anatomy of DCR**



### 2. Pre-operative preparation:

- Lignocaine spray and Nasal packing with 0.5% oxymetazoline and 4% lignocaine/proparacaine decongests the nasal mucosa

### 3. Instrumentation

- Sharp sterile instruments - periosteal elevator, bone punch
- Good lighting system and magnification (preferably loupe)
- Good monopolar and bipolar cautery and suction machine.

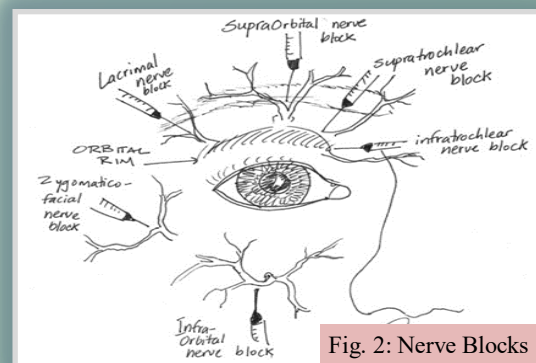
### 4. Know the bleeders

- Orbicularis (blunt dissection and holding with cat's paw retractor decreases bleeding)
- Angular vessels (better avoided at approx 10 mm nasal to medial canthus but can be sacrificed with cauterization)
- Bony perforators (suture of notha)
- Perisac plexus
- Lacrimal mucosa (infiltrate with local anesthesia, will aid in analgesia and homeostasis)
- Nasal mucosa (infiltrate with local anesthesia, will aid in analgesia and homeostasis)

### 5. Local anesthesia

- Infratrochlear nerve block
- Infraorbital nerve block
- Ethmoidal nerve block
- Dorsal nasi nerve block

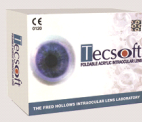Proper planning as such incision site, bone nibbling area, knowledge of anatomy, meticulously following each step and patiently dealing with bleeders (pressure, cautery or ligation) will make DCR surgery less stressful. DCR surgery is another rewarding surgery only second to cataract surgery with visible results. With proper planning and execution, DCR can be happy surgery for both the surgeon and the patient.



**Fig. 2: Nerve Blocks**

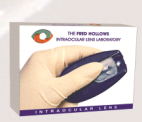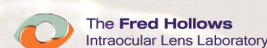### Further Readings

1. [https://www.youtube.com/watch?v=\\_7qQLGpW9ro](https://www.youtube.com/watch?v=_7qQLGpW9ro)
  2. <https://www.ncbi.nlm.nih.gov/books/NBK557851/>
  3. <https://www.nysora.com/techniques/head-and-neck-blocks/nerve-blocks-face/>
  4. Ali MJ, Naik MN, Honavar SG. External dacryocystorhinostomy: Tips and tricks. Oman J Ophthalmol. 2012 Sep;5(3):191-5. doi: 10.4103/0974-620X.106106. PMID: 23440476; PMCID: PMC3574519
- Figure 1-<http://www.oculist.net/downaton502/prof/ebook/duanes/pages/v8ch002a/008f.html>  
Figure 2 -<https://webeye.ophth.uiowa.edu/eyeforum/tutorials/retrobulbar-nerve-blocks.htm>



**FOLDABLE & PMMA Intraocular Lens**

[www.tilganga.org](http://www.tilganga.org) | [www.fhiol.com](http://www.fhiol.com) | [sales@tilganga.org](mailto:sales@tilganga.org)





## Thyroid Eye Disease (TED)



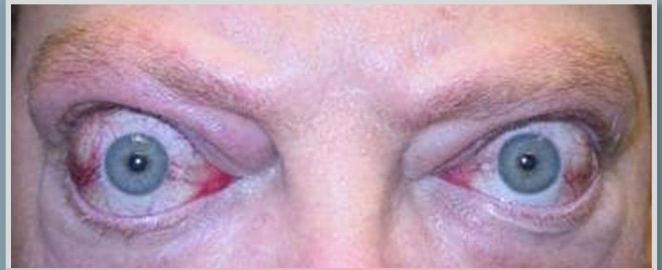Dr. Sushant Adiga, MD

**T**hyroid eye disease (TED) is a complex disease that can lead to significant ocular symptoms, facial disfigurement, and decreased quality of life. Most patients with TED have hyperthyroidism with the most common cause being Graves' disease. TED may also occur in patients with hypothyroidism (Hashimoto's thyroiditis) or euthyroidism. It affects 16 per 100,000 females and 2.9 per 100,000 males. Female gender, middle age, and smoking all have been associated with increased risk for TED.

TED is characterized by changes in the orbital soft tissue, including inflammation and remodeling. A subset of CD34+ fibrocytes infiltrate the orbit and express high levels of thyroid-stimulating hormone receptors (TSHR). These cells can differentiate into either fat cells or myofibroblasts which results in the two subtypes of TED: fat-predominant or muscle-predominant disease respectively.

The disease shows an acute inflammatory or active phase, to begin with, lasting on average for about 18 months. The inflammation then gradually subsides and the patient enters a more chronic or stable phase characterized by fibrosis.

More than 90% of patients present with eyelid retraction, the most common clinical sign. Other signs include proptosis, lid lag of the upper eyelid on down gaze (von Graefe sign), eyelid edema and erythema, conjunctival congestion, chemosis, and restrictive strabismus. The clinical presentation may commonly include symptoms of dry eye disease. In severe disease, exposure keratopathy or compressive optic neuropathy may be present. The diagnosis of TED is based on the classical clinical picture and systemic thyroid dysfunction. Orbital imaging can be used to aid in the diagnosis of TED and classification into its subtypes. Orbital computed tomography (CT) scan or magnetic resonance imaging (MRI)



Picture courtesy: <https://emedicine.medscape.com/article/383412-overview>

may show extraocular muscle involvement. Classically, the muscle belly is enlarged but the tendon is spared. The inferior rectus muscle is most commonly involved.

TED is graded by the activity and severity of the disease. Activity refers to soft tissue changes and inflammatory symptoms. It is often assessed by the clinical activity score (CAS). Treatment depends on the patient's disease activity and requires a multidisciplinary approach. Generally, treatment includes controlling thyroid hormone levels, lubricants, selenium supplementation, and minimizing risk factors that can exacerbate the disease such as smoking. Systemic corticosteroids are used in the treatment of active TED. Intravenous corticosteroids are more effective and better tolerated than oral corticosteroids. Other treatment options include systemic immunosuppressants and newer targeted therapies such as teprotumumab. Later, after the disease enters a stable phase, treatment often includes surgical correction of the residual proptosis, strabismus, and eyelid deformities.

In recent years, there have been exciting developments in the understanding and management of TED. Hence, we can expect a paradigm shift to more targeted and effective therapies in the near future.

### References:

1. Lazarus JH. Epidemiology of Graves' orbitopathy (GO) and relationship with thyroid disease. *Best Practice & Research Clinical Endocrinology & Metabolism*. 2012;26:273-9.
2. Dosiou C, Kossler AL. Thyroid Eye Disease: Navigating the New Treatment Landscape. *Journal of the Endocrine Society*. 2021 May;3:5.

In memory of  
Effi Jono  
1968-2022



*I am deeply saddened by the passing of my dear and noble friend Effi Jono, the founder of A New Vision, Singapore. Effi was a visionary leader in the world's collective journey towards eradicating cataract blindness in the developing world, and her work in championing programs towards curing blindness were exemplary. She made the world a better place, and will be sorely missed by her friends in the eye health sector. Effi founded A New Vision in 2010 in Singapore with a focus to end cataract blindness in Indonesia.*

*A New Vision was, and continues to remain one of the most important partners of Tilganga Institute of Ophthalmology. Jointly, with Effi's leadership, the two organisations have successfully cured thousands of patients living with cataracts in Nepal, Indonesia and Laos.*

*I, on behalf of the chairman of Tilganga—Mr. Suhrid Ghimire and the chairman of New Vision—Mr. Tan Ching Khoo, would like to express my deepest condolences to Effi's family. Effi was a constant source of inspiration to many that surrounded her, including me. Throughout her life, she focused on ensuring quality eye care within communities that deserved them the most. The legacy she leaves behind by curing hundreds of thousands will be fondly remembered for years to come – by me, the medical fraternity, and the patients and their families, whose lives she touched.*

*-Dr Sanduk Ruit  
Executive Director-*



## Sharing Experiences



I, Dr. Nischal Ghimire, final year resident at the prestigious Tilganga Institute of Ophthalmology and going to appear in the final examination in 2 weeks' time. My experience at Tilganga has been beyond magical, I joined TIO on Dec 2019 as a newbie in the field of ophthalmology. Being at the best eye hospital and institute of the country was a dream come true for me, even before joining the hospital I was very inspired by the professors and faculty members as I used to watch their interviews and good work they have done for the society, people of country and worldwide. I always wanted to be like them.

Once I joined the institute, I got to know more about the hospital and the faculty members. I was fascinated by their humbleness and the willing to help a newcomer like me. TIO for me was like a holy temple

where I used to go every day to gain knowledge, experience and skill. On top of that the professors, members of the faculty, my seniors they encouraged me and guided me to be more humble, sincere, punctual and honest towards work and the patients and also enlightened me what 'helping a person in need' means.

The institute has lots of patient flow and variety of cases from which I could learn every day in OPD clinics. Also faculties, consultants guided me in the operating theatre from which I could do lots of surgical procedures like cataract surgery, pterygium surgery, DCR and various other surgical procedures and also the laser procedures.

The professors and members of the faculty created such a wonderful environment that approaching them to ask or learn from them was very easy for me. The encouragement they provide us in the regular classes and presentations made me what I am today.



Date: August 31-21  
Name  
Tigist Tulu  
Senior optician

### General Comment on Biometry Training

- \* During my time at TIO, I feel like I was home. I love confidently thanks to the training managers. Specialy Mr Phandraya & Mr Shyam for being friendly & solve every problem on time.
- \* On the training aspect I get sharpened skill on biometry, B-scan & pachymetry (CCT). I believe I get better knowledge to provide training for my fellow optometrists when I get back to Ethiopia.
- \* I would like to thank every TIO staff, cleaner & gardener for everything they did, The best but not the list my favorite instructor Mr Anil & Mr. Rupes Sir for their knowledge & advanced skill transfer.


AB. Please TIO keep on the good things that increment above.

Thanks so much for every thing, TIO will be my special & favorite place ever.

It was a wonderful experience with all the wonderful people around the institute and also very helpful hospital staffs. I will always be thankful towards the Institute, professors, members of the faculty, seniors, my colleagues, academic and training department and their staff, hospital staffs for loving me and making my resident period so wonderful!

Thank You Everyone!!

## Creating a World of Difference



As a unit of Oculoplasty Department, our Ocular Prosthetic Lab completed its 11 years on this December. We keep the momentum to move forward with vision to give quality service in ocular prosthesis.

In our 11 years journey we found a very good team work. Our sincere gratitude to all the administrative team, doctors, oculoplasty surgeons, fellows, procurement team, maintenance team, fellow colleagues and last not the least our prosthesis users, we did our beautiful time with great team work together.

In this period, we attended 8,000 patient at ocular prosthetic lab. Among them, about 1,500 were fitted with custom made prosthesis and rest of patient have provided different kind of ocular prosthesis services. Not only in Nepal, our visitors are also from overseas like India, Tibet, Indonesia and Bhutan. Most probably, we are the first to introduce this practice in Nepal, where socket evaluation under the general anaesthesia were also done for those patients who were unable to take impression in normal settings. Now then, we are able to provide free of cost custom made prosthesis for the survivors of retinoblastoma with the support of OEG (Open Eye Group) Kathmandu. This service started from 2019 and about 25 survivors benefited by this programme.

### As an Ocularist, What We do?

When the artificial eye is ready to fit we only not giving foreign object or fill inside the eye socket rather we try to regain patients' self-reliance and social respect when they loose with their eye. We have several instances and experiences through practice.

Hiran Dhama, a 21 years old male, came to our ocular prosthetic lab with left eye phthisis bulbi. He lost his vision since childhood now he wants a cosmetic correction. After consultation with oculoplasty surgeon we did custom fit for him and now he is comfortable and organizing his daily schedule without any hesitation and achieved confidence and comfort than before. Unlike him, many users of such prosthetic eye gains motivation courage to do more in their life ahead.

Although, we have completed 11 years, we need to provide more than what we are doing now. As we receive numerous referrals from within the country through many eye hospitals and eye care centers, the patients rely on our services, thus, we need to update ourselves with new technology, recent materials and more customised designs to widen our services and some improvement to achieve our goal. If we all together it is possible to reach that milestone.





# Photo Gallery



**13th Nov. 2022.** On the occasion of **World Diabetes Day 2079**, Tilganga Institute of Ophthalmology organized an interactive program with media on the effect of diabetes on the eyes. Consultant ophthalmologist Dr. Raba Thapa gave detailed information about diabetes and its effects on the eyes.



**12th Nov. 2022.** As part of the **World Diabetic Day Celebration**, NEP/TIO conducted the **Cycle Rally** from Tilganga, Old Baneshwor, Thapathali, Teku to Swayambhu and return back from Swayambhu, Thamel, Kamalpokhari, Gaushala to TIO. The team joined a DR Screening Camp in Swayambhu Community Eye Center. In the cycle rally, Chief Operation Officer (COO) Mr. Pitambar Adhikari, Retina Specialist Dr. Raba Thapa and the other staffs participated.



**8th Dec. 2022.** **Himalayan Cataract Project (HCP)** and Cure Blindness team toured NEP/TIO while in Nepal for the first Asia Regional Partnership Meeting including CEO Katherine Overbey; Chief of Programs Alex Smith Davis; Monitoring, Evaluation and Learning Coordinator Anna Davidge; Ethiopia Country Director Dr. Zelalum Habtamu; and Ghana Country Representative Dr. James Addy.



**1-3 Dec. 2022.** A total of 893 people were examined, and 378 underwent free cataract surgery at Bara, Sarlahi and Rautahat. The camp was jointly organized by Nepal Red Cross Society, Nijgadh Primary Health Centre, Nijgadh Municipality, and Fred Hollows Foundation, Australia.

## Fellows - 2022/23



**23rd Dec. 2022.** A CME on **"Update on ROP- Screening and Management"** at TIO on 20th December 2022. The objective of the program was to create awareness and emphasize the significance of screening for Retinopathy of Prematurity (ROP) for prevention of ROP blindness, share all about significance of early medical treatment with injection Anti VEGF & LASER therapy & its surgical management of ROP. In the program, with 65 ophthalmic people attended including neonatologist, paediatricians & ophthalmologist from Kanti hospital, Medicity hospital, Kathmandu Medical College and TIO.



Dr. Sushant Adiga  
Orbit & Oculoplasty



Dr. Jessica Zarwan  
Cornea & External Eye Diseases



Dr. Kripa Bhattarai



Dr. Thorn Sor Sokinda  
Vitreo-Retina



Dr. Pragya Jha  
Uvea



Dr. Nisha Manandhar  
Glaucoma



Dr. Nim Lhamu Sherpa  
Vitreo-Retina



Dr. Kaushal Pokharel  
Refractive Surgery



Dr. Harish Yadav  
Medical Retina



Dr. Gunjan Prasai  
Vitreo-Retina



Dr. Anushree Adhikari  
Orbit and Oculoplasty





**Dr. Malita Amatya, MD**

## Blepharospasm: A Review

**B**enign essential blepharospasm (BEB) is a focal cranial dystonia, characterized by excessive involuntary contractions of the eyelid muscles leading to eyelid closure in the absence of any other ocular or adnexal cause which is usually bilateral, although it may be unilateral and brief at onset. The initial symptoms include unpleasant sensations, eyelid fluttering or increased blink rate to stimuli, which progresses to chronic involuntary bilateral spasms of the eyes, often so severe as to make the patient functionally blind. These symptoms are absent during sleep.

The prevalence of BEB is estimated at 36 per 10,00,000 individuals in the general populations. BEB affects women 2-3 times more frequently than men and more so in people over 50 years of age. It was noted on postmenopausal women with thyroid dysfunction and those using phenothiazines are more prone to BEB.

The exact pathogenesis of BEB is unknown, but abnormalities in the basal ganglia and corticostriatal pallidothalamic loop have been considered and also abnormal auditory brainstem response potentials have been noted. Over a period of time, as the condition progresses, spasm may involve the mid-face and neck muscles. This condition is referred to as Meige syndrome (MS). The symptoms of MS typically peak in the sixth decade of life and are seen more common in women than in men (3:2 to 2:1 ratio), with a prevalence of 5 to 10 cases per 100,000 people.

Hemifacial spasm (HFS) is a unilateral condition characterized by involuntary tonic and clonic contractions of muscles innervated by facial nerve. It occurs twice as often in women than in men with an overall prevalence of 10 per 100,000 and it usually appears in the fourth to seventh decade of life. HFS are attributed to an aberrant artery (anterior inferior cerebellar, posterior cerebellar, or vertebral) compressing seventh cranial nerve near its origin from the brainstem. HFS can be surgically corrected by microvascular decompression surgery but it potentiates the serious adverse effects.

Till date, the best method available for the initial treatment of BEB, MS and HFS is chemodenervation by Botulinum toxin type A (BTX). It retards the release of acetylcholine from the presynaptic terminals, thus blocks neuromuscular transmission at peripheral cholinergic nerve endings. It takes about 24-72 hours for onset effect after injection although it may be delayed for 2-3 weeks. It takes 3-5 days to achieve the plateau effect and the effect usually lasts for three months.

The dose of BTX is 1.25-5 units per injection site initially and may be increased if the response is not sufficient. Recovery of muscular function occurs in about three months by axonal sprouting and formation of new neuromuscular junctions.

Antibodies formed to the toxin may lead to the failure of appropriate response in 2-5% cases. This occurs when high doses are used at frequent intervals.

Adverse effects to the botulinum toxin include ecchymosis, ptosis, keratitis, epiphora, diplopia and ocular irritation. These are transient and usually do not last more than three weeks. Other less common side effects include transient increase in intraocular pressure, flulike syndrome and secondary biliary colic.

As we see many of patients with BEB and Hemifacial spasm in TIO, we conducted one year prospective study on treatment outcome of Injection Botulinum toxin in Blepharospasm. It was a hospital based, prospective, interventional study conducted on patients diagnosed as Benign essential blepharospasm (BEB), Meige syndrome (MS) and Hemifacial spasm (HFS) by oculoplastic surgeon at Oculoplasty department OPD, Tilganga Institute of Ophthalmology, from December 2018 to November 2019. After taking all standard precautions for botulinum toxin injections, 6 to 8 sites for injecting 2.5 to 5 IU of the toxin were given. All the patients were evaluated before and after injections according to Jankovic spasm grading and improvement in functional impairment scale and followed on one week, one month, three

month and when the symptoms reappeared.

A total of 43 patients who completed all the follow ups and fulfilled all the criteria were included. There were 13 (30.2%) males, with mean age of 58.38 years  $\pm$  10.437, 30 (69.8%) females with mean age of 60.30 years  $\pm$  10.557. There were 32 (74.4%) cases of BEB, 9 (20.9%) HFS and 2 (4.7%) MS. There was involvement of right eye (OD) in 3 (7.0%), left eye (OS) in 7 (16.3%) and both eyes (OU) in 33 (76.7%). The involved patients were from all parts of Nepal, 13 (30.3%) from within Kathmandu valley. They were mostly by farmer in occupation comprising 20 (46.5%) of all the study population.

The mean Jankovic severity score was  $3.51 \pm 0.51$  (range 3-4). The mean improvement in functional score was  $2.60 \pm 0.54$  (range 1-3), was statistically significant (p-value <0.001). All patients experienced decrease in spasm within one week and relieved from symptoms after Botulinum toxin injection, is statistically significant. The average effective period was a minimum of 93 days, maximum of 189 days with a mean of  $127.55 \pm 19.860$  days. There was no significant change in the intra ocular pressure (IOP) on the follow-ups compared to the pre-injection level, as all were within the normal ranges. Improvement in the levator function was observed on the right eye which was statistically significant (p-value 0.012). We have found that our patients had dry eyes on Schirmer's test I testing.

Four patients had minimal side effects of - injected site redness and hematoma at one site which appeared on the day of injection and completely resolved by one week by itself. No patient complained of any systemic side effects. 38 patients had repeated injections after reappearance of symptoms.

The limitations of our study included no study on repeat injections, fairly good numbers of patients were enrolled due to lack of promise to regular follow-ups and low patient compliance. The only drawback of botulinum toxin is that the effect of injection wears off in an average of 12 weeks and it has to be repeated every 3-4 months which is financially burdensome. This needs the patient's motivation and understanding the lasting duration of toxin effect, affordability, availability of injection in the centre.

**Conclusion:** Botulinum toxin type A is the first line treatment of choice for Blepharospasm, Hemifacial spasm and Meige syndrome and is effective and safe for temporary treatment available today. Its duration of effect ranges from 93 to 189 days with significant improvement within 1 week and minimal local side effects.

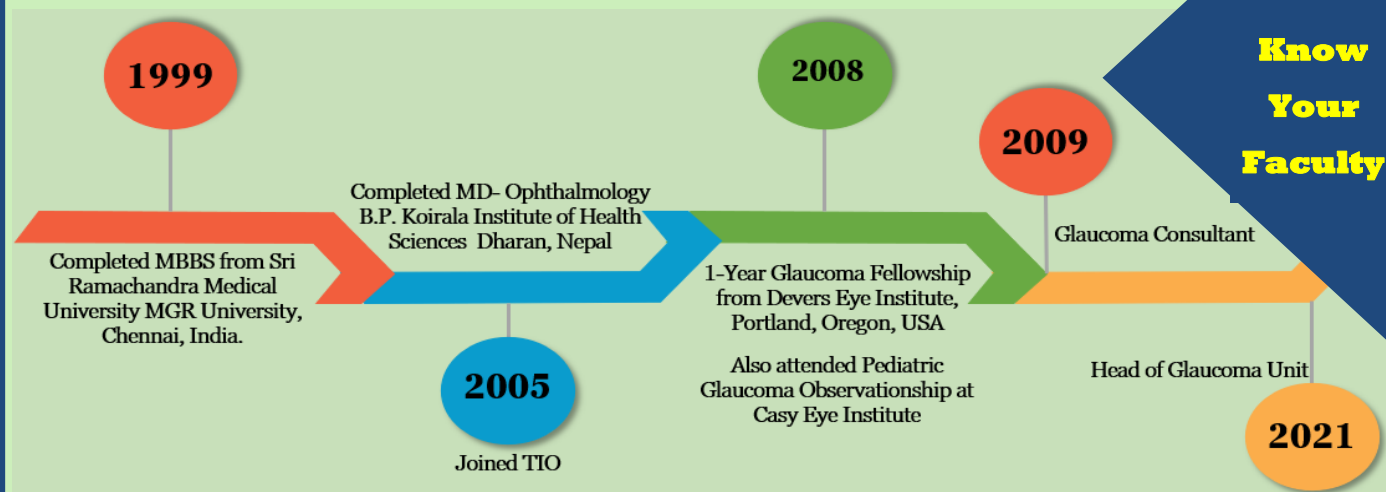
### References:

- Amatya M et al Outcome of Injection Botulinum Toxin in Blepharospasm Nepal J Ophthalmol 2021; Vol 13 (25): 40-49
- Choe WJ, Kim J (2016). Increasing the area and varying the dosage of Botulinum toxin injections for effective treatment of hemifacial spasm. Acta Otolaryngologica. Doi: <http://dx.doi.org/10.3109/00016489.2016.1165864>.
- Czyz CN, Burns JA, Petrie TP, Watkins JR, Cahill KV, Foster JA (2013). Longterm Botulinum Toxin of Benign Essential Blepharospasm, Hemifacial Spasm, and Meige Syndrome. American Journal of Ophthalmology; 156(1):173-177.
- Zhou B, Wang J, Huang Y, Yang Y, Gong Q, Zhou D (2013). A resting state functional magnetic resonance imaging study of patients with benign essential blepharospasm. J Neuroophthalmol; 33(3):235-24
- Christian D, Bernhard H, Florian C, Afra M W, Andre O (2006). Silent-event-related fMRI reveals deficient motor & enhanced somatosensory activation in orofacial dystonia. Brain; 129(1):36-46.
- Jankovic J, Comella C, Hanschmann A, Grafe S (2011). Efficacy and safety of Incobotulinum toxin A in the treatment of Blepharospasm. Movement disorders; 26 (8):1521-1528.
- Jankovic J, Hallet M (1994). Therapy with botulinum toxin. New York, Hong Kong. Marcel Dekker:191-197
- Truong DD, Comella C, Fernandez HH, Ondo W (2008). Efficacy and safety of purified botulinum toxin type A for the treatment of benign essential blepharospasm: A randomized, placebo-controlled, phase II trial. Parkinsonism and related disorders; 14:407-414.



**Assoc. Prof. Dr. Indira Paudyal**, from Pokhara, is currently the head of glaucoma department, and the head of Quality Assurance (QA) - hospital services of Tilganga Institute of Ophthalmology (TIO). She has been involved in training MD residents, and many national and international fellows of glaucoma. She is involved high volume cataract surgical camps through OMEC. She has been a national and international trainee for cataract surgery (SICS and Phaco) since 2009. Recently, she became the mentor for CATQUIIP-2022. She has published over 10 articles in many national and international indexed journals. She has received the most prestigious —ARVO ‘WEVER’ Award for developing country in Fort Lordadele, USA.

**Dr. Paudyal** has major contribution in Bhaktapur Glaucoma Study (BGS). She has attended numerous conferences, workshops and scientific presentations both nationally and globally. Since 2005, she has been actively involved in glaucoma awareness activities through Glaucoma Support Group Nepal. She is the founder executive member of World Ophthalmologist Women Society and the General secretary of Glaucoma Society of Nepal (GSN). She is the Improvement Coach for Professional Development - from Institute for Healthcare Improvement (IHI). Recently, she was felicitated during installation ceremony of new ACOIN president in Kashmir—2022. Her special interests includes travelling and gardening.

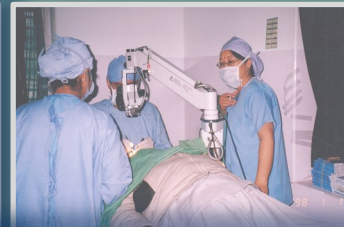

## The Staff Insight: Ms. Karuna Shrestha

**Please introduce yourself :** Namaste! I'm Karuna Shrestha completing 30 years of my services to Tilganga. I completed Intermediate of Science and completed Ophthalmic Science. I joined in the year 1990. I stay at Lalitpur with my husband. I have a son, daughter-in-law and a lovely grand-daughter of 4 years. I enjoy devotional songs and social activities.

**The Most Happiest Moment:** About 25 years ago in Nuwakot Eye Camp, a 34-year-old woman underwent cataract surgery. As a result of the surgery, she was able to see her child for the first time in her life. I felt so happy for her and moved to tears by the joy that she was experiencing. This brought chance to work with **Prof. Fred Hollows**. Similarly, 9 years back, I was grateful for the opportunity to receive **Jagat Guru Sri Kripalu Maharaj**, a spiritual leader, late night at 1:00am. His visit and presence to the TIO is a true blessing. Furthermore, I am happy to rejoice my earlier days which led me to travel various countries like India, China, Bhutan, Laos, Indonesia, DPRK, Cambodia, Singapore and Australia throughout my job to tackle avoidable blindness, visual impairment and for academics.

**Experience during early days at TIO:** Tilganga is my second-to-none home and holds a special place in my heart. I was mostly engaged with eye camps but I was involved with any works related to Tilganga though I was Supervisor. My first salary was 3,000 NPR per month which was so huge and a proud moment!



**Tilganga Then and Now:** Earlier, I enjoyed being a workaholic and derived pleasure from my work. However, as I have gotten older, there are more administrative and clinical pressures and tasks that have made it difficult for me to fully enjoy my work. I feel overwhelmed or burnt out due to the increased demands of the job. I try my best to enjoy at this age!

**Any concluding remarks?** I wish the best wishes to my Tilganga, my prayers that it constantly progresses beyond eternity. To add, I wish to do my eye treatment here itself. I thank everyone throughout my TIO journey!



# Thank You



13th Oct. 2022. World Sight Day (WSD) celebration at Curative Service Division, Department of Health Services under Ministry of Health and Population.



22st Dec. 2022. NEP/TIO is honored to welcome Dr. Rajesh Sambhajirao Pandav, WHO Representative to Nepal and Dr. Lonim Prasai Dixit, National Professional Officer, WHO Nepal today. They observed the entire facilities and services of NEP/TIO followed by meeting with Prof. Dr. Sanduk Ruit, executive team and department heads.

20th Dec. A MoU has been signed with NEP/TIO and social worker, Mr. Gauri Shankar Chowdhury to establish Tilganga Community Eye Center Nichuta, Parsa - a branch of the Hetauda Community Eye Hospital. Mr. Chowdhury has donated land in Perteva Sugauli village at Parsa.



Artwork By: Dr. Sushant Adiga



12th Oct. New World Medical donated sight saving glaucoma surgical devices and implants to NEP/TIO.



16th Nov. NEP/TIO is honoured to welcome Her Excellency Ambassador and Head of the Delegation of the European Union to Nepal, Ms. Nona Deprez.




11-12 Dec. NEP/TIO organized Cataract Quality Improvement Intensive Project (CatQIIP) Learning Session-III with financial support of the Fred Hollows Foundation. The participants were medical directors and team from 8 different partner hospitals from 7 provinces. This event was followed by CATQIIP visit to 4 hospitals.



20th Oct. 2022 Rotary Club of Bagmati (RCB) donated NPR One hundred thousand to NEP/TIO for retina treatment through injection Avastin to underprivileged patients. The cheque was handed over to Dr. Reeta Gurung, CEO of NEP/TIO by Rajesh Mani Ghimire, President of RCB. Dr. Eli Pradhan, consultant ophthalmologist & medical retina specialist, extended her generous financial support to needy patients.

## Outreach Microsurgical Eye Clinic-Year 2022

63,525 Screening 6,694 Sight Restoration in 2 Countries



For Subscription, Articles and Feedback: Email at: [krishna.shrestha@tilganga.org](mailto:krishna.shrestha@tilganga.org) / [info@tilganga.org](mailto:info@tilganga.org)  
Editorial Team: Dr. Eli Pradhan, Krishna Gopal Shrestha and Birendra Mahat